

## Artículo original

# Renal fungal balls in children. A study of nine cases

Oscar Vázquez-Tsuji MD,\* Teresita Campos-Rivera MD,\* María Antonieta Mora Tiscareño MD,\*\* Héctor Ahumada-Mendoza MD,\*\* Ignacio Martínez-Barbabosa MD,\*\*\* Gabriel Cardoso-Hernández MD\*

### Resumen

**Antecedentes:** La presencia de las bolas fúngicas renales causadas por *Candida* se ha informado con poca frecuencia. El diagnóstico se basa en la evidencia ultrasonográfica de las lesiones y en el cultivo de orina positivo. El manejo más común es el quirúrgico; sin embargo, algunos autores han señalado el uso de antimicóticos con diferentes resultados.

**Métodos:** Se revisan los casos de nueve niños con diagnóstico de sepsis por *Candida* y bolas fúngicas renales.

**Resultados:** De los nueve pacientes, cuatro eran recién nacidos, dos lactantes menores, dos mayores y un adolescente. En seis de los casos existió el antecedente de cirugía previa a la sepsis y a las bolas fúngicas renales. En todos los casos, las muestras de orina resultaron positivas en el examen directo para el pseudomicelio de *Candida*. El cultivo de orina fue positivo en siete casos y negativo en dos (< 10,000 UFC/ mL). El ultrasonido mostró la presencia de bolas fúngicas en los nueve casos, con un aumento de la ecogenicidad renal en seis, dilatación caliceal en tres y alteración de la relación corticomedular en dos. Los pacientes se trataron con anfotericina B o con fluconazol, hasta la desaparición de las lesiones. Ninguno de los pacientes requirió tratamiento quirúrgico renal.

**Conclusiones:** El diagnóstico de bolas fúngicas renales se puede realizar mediante ultrasonido y urocultivo. Se debe descartar la presencia concomitante de candidiasis renal en los pacientes que cursen con sepsis por *Candida*. Como parte del abordaje diagnóstico se debe realizar la búsqueda de pseudomicelio en la orina. La respuesta al tratamiento antimicótico en pacientes con bolas fúngicas es satisfactoria si se administra en etapas tempranas de la enfermedad.

**Palabras clave:** Bolas fúngicas renales, candidiasis, cultivo de orina, ultrasonido, tratamiento antimicótico.

\* Department of Parasitology and Mycology.

\*\* Department of Radiology.

Instituto Nacional de Pediatría, Mexico.

\*\*\* Department of Health Attention, Universidad Autónoma Metropolitana-Xochimilco, Mexico.

Corresponding author: Óscar Vázquez-Tsuji MD. Departamento de Parasitología y Micología. Instituto Nacional de Pediatría. Insurgentes Sur 3700-C, Col. Insurgentes Cuicuilco, 04530, México DF, México. Tel: 56 06 00 02 ext. 336. Fax: 56 06 79 73.

Recibido: enero, 2002. Aceptado: marzo, 2002.

### Abstract

**Background:** The presence of renal fungal balls caused by *Candida* is a seldom-reported pathology. The diagnosis is based on the ultrasonographic evidence of the lesions and on a positive urine culture. The most common management is surgical; however, some authors have resorted to the use of antimycotics with different results.

**Methods:** Nine children with hospital acquired confirmed *Candida* sepsis and renal fungal balls were studied.

**Results:** Four of the nine patients were newborn, two were young infants, two were older infants and one, adolescent. A surgical procedure was performed on six of the patients before the development of sepsis and renal fungal balls. Urine specimens were positive for pseudomycelia and *Candida* yeast in every case; a urine culture was positive in seven cases and negative in two. Ultrasound studies demonstrated the renal fungal balls in every patient; there was increased renal echodensity in six; caliceal dilatation in three and an altered cortico-medular relation in two. The patients were treated with amphotericin B or with fluconazol. The outcome was successful and the fungal balls disappeared. None of the patients required a renal surgical procedure.

**Conclusions:** The diagnosis of renal fungal balls must be based on ultrasound studies and urine cultures. We propose that the presence of renal fungal balls in patients with *Candida* sepsis should be discarded and that part of the diagnostic approach should include the search of pseudomycelia in the urine. The response of an antimycotic treatment in patients with fungal balls is satisfactory if given in the early stages of the disease.

**Key words:** Renal fungal balls, candidiasis, urine culture, ultrasonographic studies, antimycotic treatment.

### Introduction

Renal candidiasis is the result of the hematogenous dissemination of the fungus in the kidneys during an episode of candidemia or else of an ascendant urinary infection.<sup>1</sup>

Renal involvement following sepsis by *Candida* occurs in as many as 85% of the cases. Nevertheless, the infection may be limited to the kidneys.<sup>2</sup>

Renal candidiasis may present as a variety of clinical conditions such as pyelonephritis, papillary necrosis, renal abscess, perinephritic abscess and fungal balls. The presence of fungal balls may be associated with partial or total urinary obstruction, hydronephrosis and ureteral dilatation.<sup>3,10</sup>

In renal candidiasis with fungal balls, the clinical findings depend on the degree of obstruction. The most alarming presentation may be an episode of urinary retention with oliguria or anuria in cases with obstructive bilateral involvement caused by the fungus.<sup>4</sup> Renal involvement is relatively common in *Candida* sepsis, but acute renal failure is only caused by fungal obstruction. Fortunately, in most cases, the clinical course is not so severe.<sup>1</sup>

A delayed diagnosis of renal candidiasis results in greater severity of the lesions and complications; thence the importance of reorientating the diagnosis in patients in whom this pathology is suspected.<sup>5,6</sup>

One of the parameters for the diagnosis of *Candida* renal tract infection is the presence of more than 10,000 colony-forming units per milliliter (UFC/mL) in specimens obtained from urine containers. However, the most reliable method for the diagnosis is the presence of fungal balls demonstrated in renal ultrasound studies. Fungal balls are seen as echogenic foci within the collector systems without acoustic shadows in renal sonograms.<sup>3,7,8</sup>

The classical treatment for this condition has been surgical; however, recent reports on the use of systemic antimycotics such as fluconazol and amphotericin B show successful results.<sup>9</sup>

The purpose of this report is to present the clinical and laboratory spectrum of this condition and to discuss the criteria for its diagnosis and treatment.

## Methods

The clinical charts of patients with the diagnosis of sepsis by *Candida* and renal fungal balls were studied. These patients had been hospitalized at the Instituto Nacional de Pediatría (National Institute of Pediatrics of Mexico City) between the 1<sup>st</sup> of January of 1999 and the 31<sup>st</sup> of December, 2000. There were 14 cases of renal fungal balls; nine of these were included in the study because they had blood culture, serum galactomanan, serum antigen study for *Candida* by monoclonal antibodies, search for pseudomycelia in urine and renal ultrasound. These patients were identified in the Departments of Surgery, Intensive Care Unit, Infectology

and Neonatology. The date of diagnosis was placed on the day a positive ultrasound was recorded, in addition to a positive blood or urine culture for *Candida*.

A positive renal ultrasound study was defined as one exhibiting fungal balls reported as hyperechoic areas measuring a minimum of 3 mm in diameter, located within the renal collector system.

A positive ultrasound study for fungal balls in a patient able to produce urine was indicative of an incomplete obstruction.

A urine culture was considered positive when: 1) there were >1,000 *Candida* colonies obtained through direct bladder catheterization or by suprapubic aspiration; 2) there were >1,000 *Candida* colonies obtained from urine collected in a urine container.

Sepsis by *Candida* was defined as the growth of *Candida* in a blood culture and/or by the presence of serum mannan antigen for *Candida* for monoclonal antibodies in febrile or hypothermic patients; in those hemodynamically unstable, and with laboratory data consistent with sepsis.

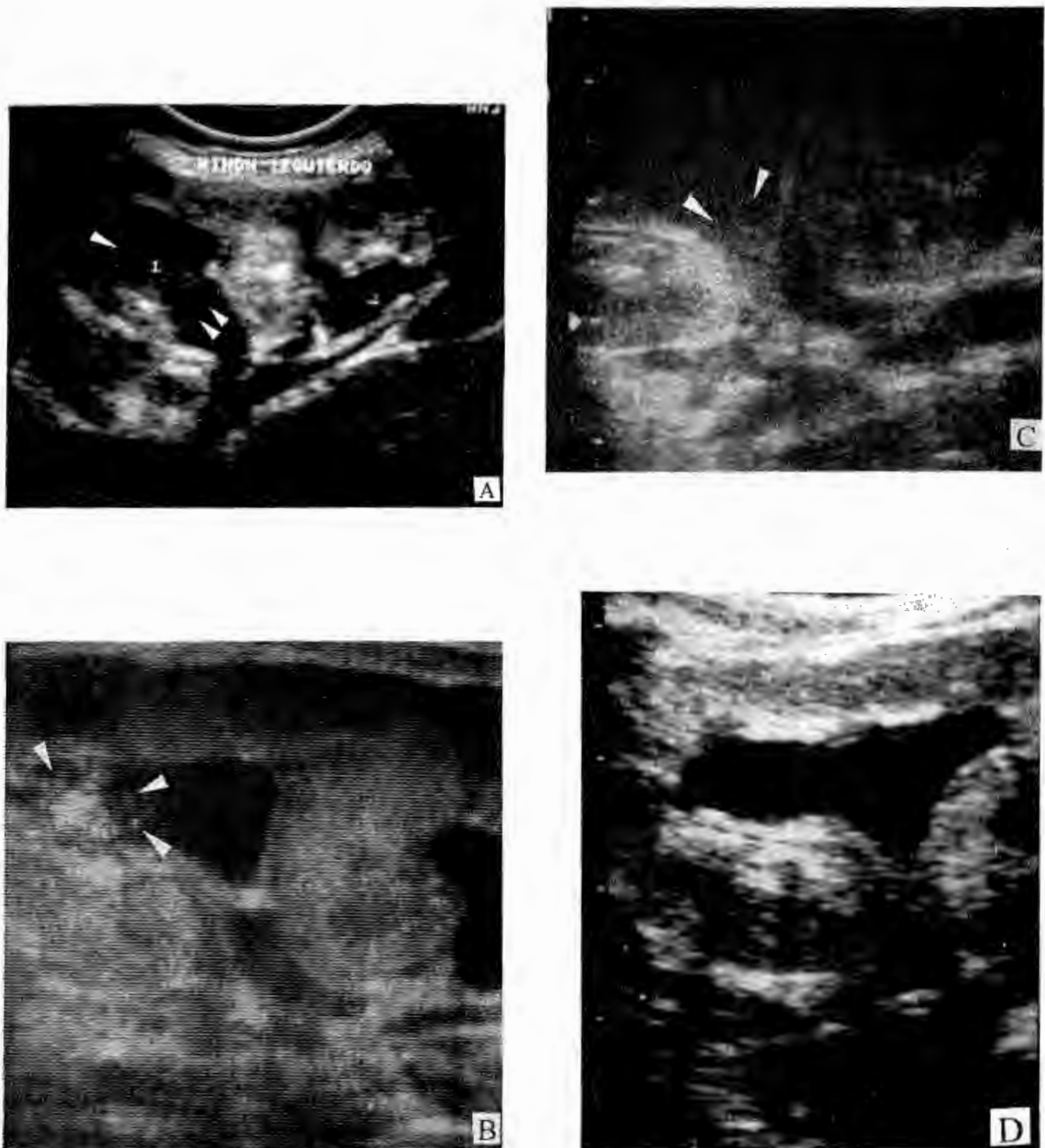


Figure 1. Microphotograph depicting the presence of abundant *Candida* sp. pseudomycelia in direct examination of centrifuged fresh urine.

## Results

Of the nine patients, four were newborn; two, young infants; two, older infants and one, adolescent. Six were male. Every patient had candidemia proven by positive blood cultures. Seven of the cases were positive for *C. albicans*; one, for *C. parasilopsis* and one, for *C. tropicalis* (Table 1).

Of the nine cases with a positive blood culture, eight were positive for detection of serum *Candida* antigen. The case with a negative study for antigen detection was identified by biochemical tests as *C. albicans*.



**Figure 2.** Sonogram of the left kidney in case # 2. **A.** Notice the double collector system showing a hyperechogenic spheric image without an acoustic shadow; it is indicative of a fungal ball occluding the superior collector. An increased echogenic renal cortex is also present. **B.** Sonogram of the same case, depicting the lysis of a fungal ball in the upper left renal collector system and increased renal echogenicity. **C.** Total disappearance of the fungoma in the superior collector group; only detritus of the fungoma are seen with recovery of normal echogenicity of the kidney. **D.** Complete recovery after 34 days of treatment with fluconazol.

In six of the cases with *Candida* sepsis there was a history of a surgical procedure a few days prior to the development of mycotic sepsis and renal fungal balls.

Direct examination of the urine of the nine patients revealed the presence of *Candida sp.* yeasts and pseudomycelia with a predominance of the latter (Fig 1).

Urine culture in terms of the number of UFC/mL was positive in seven cases and negative in two. The ultrasound study revealed the presence of renal fungal balls in every case; in addition, six cases exhibited increased echogenicity of the renal parenchyma bilaterally; caliceal dilatation in three, and an altered cortico-medullar relation in two.

Five patients were treated with amphotericin B at the dose of 1 mg/kg/day, a total cumulative dose (TCD) between 26 and 35 mg/kg and a mean TCD of 30.3 mg/kg. Four patients were given fluconazol: 6 to 10 mg/kg/day over a period of 33 to 37 days and a mean of 34 days. No patient required renal surgery.

Direct examination of centrifuged urine in search of pseudomycelia was negative eight days after the initiation of antimycotic treatment in six patients; 10 days in two cases and 12 days in one case.

Renal fungal balls disappeared gradually in every patient with a slow elimination of detritus as seen in ultrasound studies (Figure 2).

## Discussion

The presence of candiduria in a patient may be the result of: a) colonization of the genitourinary tract; b) a primary candidiasis cystitis; c) pyelonephritis; d) the presence of fungal balls; e) mycotic abscesses. Unfortunately, there is no reliable and simple way to differentiate among these possibilities.<sup>1,11</sup>

In view of these circumstances, the diagnosis of *Candida* infection of the urinary tract has been approached with different criteria. One of the most valuable is the count of *Candida* colonies forming units in urine cultures to ascertain that a fungal urinary infection is present. A positive diagnosis of a mycotic urinary infection in urine specimens obtained from a collecting container is a count >10,000 UFC/mL.

In the case of bacterial urinary infection, a count of >100,000 UFC/mL is also diagnostic. However, the range of UFC varies from 10<sup>4</sup> to 10<sup>5</sup> per milliliter; these figures in the study of Kass does not indicate the presence or absence of urinary infection. In other words, the figures within this range cannot assert nor deny the presence of a bacterial

urinary infection.<sup>12</sup> The same situation may exist in cases of *Candida* urinary infection. Yet, there are no studies indicating the range of unpredictability in cases of renal candidiasis. Within this range, unpredictability may occur in an undetermined number of patients with *Candida* urinary infections.

It should be kept in mind that the criterion for a positive diagnosis of *Candida* infection, i.e., the presence of >10,000 UFC/mL colonies is merely an extrapolation of the standard applied for bacteria.<sup>3</sup>

The lack of these studies is due primarily to the fact that this entity is seldom diagnosed; consequently, it is very difficult to undertake prospective studies in order to clarify the problem. In most of the reports on *Candida* urinary infection the diagnostic approach is based on the identification of blastoconidia (yeasts) and on the number of UFC/mL in *Candida* cultures. However, a specific search on the diagnostic significance of the presence of *Candida* pseudomycelia in the urine has not been done. The presence of pseudomycelia in urine tangles has been reported as extremely rare; when present, it is indicative of an upper urinary tract infection.<sup>13</sup>

We believe that the specific search for pseudomycelia in urine is very important, based on the fact that the pseudomycelia stage originating from the yeast-like stage is the way fungi avoid phagocytosis. This facilitates tissue fungal invasion. Yeasts are the saprophytic forms; pseudomycelia are the pathogen or parasitic form predominant in the tissues.<sup>14-16</sup>

In our nine cases, we detected abundant yeasts and pseudomycelia elimination in centrifuged urine specimens. On the other hand, in two of the cases the count of *Candida* colony forming units per milliliter could have been considered as "negative" (<10,000 UFC/mL); however, the presence of abundant pseudomycelia was suggestive of an invasive process. Ultrasound studies had not been performed, these two cases would have been regarded as instances of urinary colonization and their treatment for *Candida* sepsis would have been limited to between 14 and 21 days at the most; the renal problem would not have been resolved and the prognosis endangered.

"Low" counts of UFC/mL may be due to partial obstruction caused by pseudomycelia tangles in the collecting system such as occurs in cases of bacterial urinary infections with obstructive uropathy in which low counts of UFC/mL have been reported.

Therefore, it is important to provide adequate training to laboratory technicians for insuring an accurate intentional search of pseudomycelia in urine specimens; a simple report of the presence of yeasts is unsatisfactory since there may be cases where pseudomycelia are present and their importance is underestimated.

Yet, there is no consensus on the treatment of this condition. Several authors advocate a parenteral treatment and the use of irrigation with amphotericin B; they stress the need for surgical removal of pelvi-caliceal mycelia. On the other hand, there are reports of medical treatment with fluconazol, some successful, some followed by relapse and some unsuccessful.<sup>17</sup> In our patients, the use of fluconazol at the dose of 6 to 10 mg/kg/day or amphotericin B at the dose of 1 mg/kg/day was successful. It is of interest that our patients were diagnosed at an early stage; none of them suffered either severe obstruction or anuria, a fact that had a direct favorable influence on the good response to the antimycotic treatment and prevented complications requiring surgical management.

The duration of antimycotic treatment has not been established. We propose that it should be given until direct centrifuged urine specimen and urine cultures are negative for the presence of the fungus. Likewise, the diagnostic parameter of the presence of fungal balls in ultrasound studies should be used following antimycotic treatment when these fungal balls disappear.

A history of an abdominal surgical procedure was an added risk factor in six of our nine patients for the development of *Candida* sepsis as has been reported by some authors.<sup>18</sup> Our report is the first in which several cases in whom a prior history of abdominal surgery was also a risk factor for the development of renal fungal balls.

We suggest that the diagnostic approach of every patient with *Candida* sepsis should include the search of other mycotic infection foci, since these require a longer antimycotic treatment. Indeed, the conventional treatment of 14 to 21 days for uncomplicated *Candida* sepsis are insufficient for a successful outcome in cases with such complications as osteomyelitis, arthritis, central nervous system candidiasis or renal candidiasis.

Finally, we suggest that the diagnostic approach for renal *Candida* infectious foci should include the search of pseudomycelia in serial centrifuged urine specimens in addition to the count of colonies in urine cultures and renal ultrasound.

#### REFERENCES

1. Lauter J, Reichman B, Graif M, Brish M. Anuria in a premature infant due to ureteropelvic fungal bezoars. *Eur J Pediatr* 1986;145:125.
2. Gerle RD. Roentgenographic features of primary renal candidiasis. *AFR* 1973;119:731.
3. Bailey JE. Neonatal candidiasis: The current challenge. *Clin Perinatol* 1991;18:263.
4. Eckstein CW, Kass EJ. Anuria in a newborn secondary to bilateral ureteropelvic fungus balls. *J Urol* 1982;127:109.
5. Baetz-Greenwalt B, Kumar ML. Bladder fungus balls: A reversible cause of neonatal obstructive uropathy. *Pediatrics* 1988;81:826.
7. Matsumoto AH, Dejter SW, Barth KH, Gibbons MD. Percutaneous nephrostomy drainage in the management of neonatal anuria secondary to renal candidiasis. *J Pediatr Surg* 1990;25:1295.
8. Kintanar C, Cramer BC, Reid WD, Andrews WL. Neonatal renal candidiasis: Sonographic diagnosis. *AJR* 1986;147:801.
9. Stuck KJ, Silver TM, Jaffe MH, Bowerman RA. Sonographic demonstration of renal fungus balls. *Radiology* 1981;142:473.
10. Babut JM, Coeurdacier P, Bawab F, Treguier C, Fremont B. Urinary fungal bezoars in children. Report of two cases. *Eur J Pediatr Surg* 1995;5:248.
11. Coria LJJ, Vázquez TO, Rosibell CM, Campor RT. Usos clínicos de la anfotericina B. *Acta Pediatr Mex* 1999;20:304.
12. Hernández ChA, López GP, Corona JF, Hernández JA, Hernández HJ, Macías IA. Tratamiento de la candiduria en pacientes en estado crítico. Estudio comparativo entre fluconazol vía oral y anfotericina B en irrigación. *Rev Med IMSS* 1995;33:457.
13. Kass EH. Asymptomatic infections of the urinary tract. *Trans Assoc Am Phys* 1956;69:59.
14. Sobel DJ. Candiduria. En: Schlossberg D. Current therapy of infectious disease. USA: Mosby 1996; p194.
15. Louria DB, Bryton RG. The behaviour of *Candida* cell within leucocytes. *Pro Soc Exp Biol Med* 1964;115:93.
16. Montes L, Wilborn WH. Ultrastructural features of host parasite relationship in oral candidiasis. *J Bacteriol* 1968;96:1349.
17. Montes L, Wilborn WH. Fungus-host relationship in candidiasis. A brief review. *Arch Dermatol* 1955;121:119.
18. Hitchcock IRJ, Pallet A, May AM, Malone JSP. Urinary tract candidiasis in neonates and infants. *Br J Urol* 1995;76:252.
19. Wey SB, Mori M, Pfaller MA. Risk factors for hospital-acquired candidemia. A matched case-control study. *Arch Intern Med* 1989;11:2349-53.

## Fe de erratas

### Enfermedad de Gaucher. Estudio de 14 niños

En el artículo **Enfermedad de Gaucher. Estudio de 14 niños** (Acta Pediátrica de México 2002;23[2]:73-80) algunos datos aparecen incorrectos, por lo que se hacen las siguientes aclaraciones:

#### Página 76:

*Dice:*

#### Resultados

... Hubo 11 pacientes con enfermedad de tipo I (79%), dos pacientes con tipo II (21%) y ninguno de tipo III (cuadro 1); todos tenían esplenomegalia, ...

*Debe decir:*

#### Resultados

... Hubo 11 pacientes con enfermedad de tipo I (79%), tres pacientes con tipo II (21%) y ninguno de tipo III; todos tenían esplenomegalia, ...

#### Página 77 (penúltimo párrafo)

*Dice:*

En este estudio las alteraciones neurológicas ocurrieron en el tipo II: dos casos con deterioro mental progresivo, dos con estrabismo, uno con espasticidad y uno más con crisis convulsivas (cuadro 4).

*Debe decir:*

En este estudio las alteraciones neurológicas ocurrieron en el tipo II: dos casos con deterioro mental progresivo (14%), dos con estrabismo (14%), uno con espasticidad (7%) y uno más con crisis convulsivas (7%) (cuadro 4).

#### Página 78 (cuadro 5)

*Dice:*

13	(+)	(+)					(+)
14	(+)	(+)					
Total	14	10	7	3	6	2	3
%	100 %	71 %	50 %	21 %	43 %	14 %	21 %

*Debe decir:*

13		(+)					(+)
14		(+)					
Total	12	10	7	3	6	2	3
%	85 %	71 %	50 %	21 %	43 %	14 %	21 %

#### Página 79 (primer párrafo)

*Dice:*

En este estudio, el mayor número de casos se diagnosticó por la determinación de fosfatasa alcalina (85%)...

*Debe decir:*

En este estudio, el mayor número de casos se diagnosticó por la determinación de fosfatasa ácida (85%)...

### Renal fungal balls in children. A study of nine cases

En el artículo **Renal fungal balls in children. A study of nine cases** (Acta Pediátrica de México 2002;23[2]:68-72) se omitió el cuadro 1, el cual aparece en las páginas 204 y 205.

#### Página 69

*Dice:*

... 2) there were > 1,000 *Candida* colonies obtained from urine collected in a urine container.

*Debe decir:*

... 2) there were > 10,000 *Candida* colonies obtained from urine collected in a urine containers.

Table 1. Cases of *Candida* sepsis with renal fungal balls

Case	Age	Sex	Reason of hospitalization	Isolation in blood culture	Pseudomycelium in urine	Urine culture	Detection of antigen	Initial renal ultrasound	Treatment prescribed. Duration	Final renal ultrasound
1	27 d	M	Neonatal sepsis	<i>C. parasilopsis</i>	+	+	+	Bilateral fungal balls	Amphotericin B 1 mg/kg/day TCD 30 mg/kg	Disappearance of the fungal balls
2	24 m	F	Gastrostomy	<i>C. albicans</i>	+	-	+	Bilateral fungal balls, bilateral pyelocaliectasia, altered cortico-medullar relation, dilated left ureteral tract	Fluconazol 6 mg/kg/day 34 days	Disappearance of the fungal balls, persistence of the dilatation of the collectors system with dilated left ureteral tract
3	26 d	m	Esophageal plasty	<i>C. albicans</i>	+	+	+	Bilateral fungal balls and generalized increased echogenicity of both kidneys with some prominent pyramids	Amphotericin B 1 mg/kg/day TCD 30 mg/kg	Disappearance of the fungal balls, recovery of normal echogenicity, morphological normal kidneys
4	20 d	M	Gastroschisis. Abdominal wall closure	<i>C. albicans</i>	+	+	+	Bilateral fungal balls and increased echogenicity of both kidneys	Amphotericin B 1 mg/kg/day TCD 30 mg/kg	Disappearance of the fungal balls in both kidneys with recovery of normal echogenicity
5	16 m	F	Bronchopneumonia	<i>C. albicans</i>	+	+	+	Bilateral fungal balls and generalized increased echogenicity of both kidneys	Amphotericin B 1 mg/kg/day TCD 26 mg/kg	Disappearance of the fungal balls in both kidneys and recovery of normal echogenicity
6	2 m	F	Sepsis. Down's syndrome	<i>C. tropicalis</i>	+	-	+	Bilateral fungal balls in the pelvices and bilateral increased echogenicity	Amphotericin B 1 mg/kg/day TCD 35 mg/kg	Disappearance of the fungal balls, recovery of normal echogenicity

7	5 m	F	Vesical extrophy. Vesicostomy, colostomy	<i>C. albicans</i>	+		+	+	Bilateral fungal balls and bilateral dilatation of caliceal groups	Fluconazol. 19 mg/kg/day 37 days	Disappearance of the fungal balls in both kidneys with persistence of dilatation of caliceal groups
8	17 d	F	Intestinal occlusion and intestinal resection	<i>C. albicans</i>	+		+	+	Bilateral fungal balls and hyperechoic parenchyma	Fluconazol. 10 mg/kg/day 33 days	Disappearance of the fungal balls, recovery of echogenicity
9	14 y	F	Exploratory laparotomy. Neuroectodermic tumor	<i>C. albicans</i>	+		+	-	Bilateral fungal balls and increased echographic pattern with ectasia of collector groups in both kidneys	Fluconazol. 10 mg/kg/day 32 days	Disappearance of the fungal balls, normal shape and position of the kidneys