

Artículo original

Radiologic patterns in the early stages of pulmonary aspergillosis. A study of 15 children

Dr. Óscar Vázquez-Tsuji,* Dra. María Antonieta Mora-Tiscareño,** Dra. Iraida Orozco-Loza,*** Dra. Teresita Campos-Rivera,* Dr. Ignacio Martínez-Barbabosa,**** Dra. Arsheli Rojas-Garrido,¹ Dra. Angélica Monsiváis-Orozco²

Resumen

Antecedentes: La aspergilosis es una micosis oportunista causada por especies de *Aspergillus*. Afecta preferentemente a pacientes severamente inmunocomprometidos con neutropenia acentuada.

Objetivo: Describir las imágenes radiológicas de la aspergilosis pulmonar en casos diagnosticados tempranamente, mediante la detección de antígeno galactomanan con anticuerpos monoclonales para especies de *Aspergillus*.

Material y métodos: Se incluyeron los expedientes clínicos y radiológicos de pacientes masculinos y femeninos, que estuvieron hospitalizados en el Instituto Nacional de Pediatría, con edades comprendidas de un día de vida hasta 18 años, con diagnóstico clínico y radiológico de aspergilosis confirmado mediante la detección de antígeno galactomanan con anticuerpos monoclonales para especies de *Aspergillus* en el suero. Se analizaron radiografías de tórax previas y posteriores al diagnóstico.

Resultados: Los patrones radiológicos observados antes del diagnóstico fueron: infiltrado intersticial puro, infiltrado intersticial relacionado con reforzamiento peribronquial, reforzamiento peribronquial puro, infiltrado parahiliar con consolidación, infiltrado intersticial con consolidación alveolar y radiología normal. Los patrones radiológicos encontrados al momento del diagnóstico etiológico fueron: infiltrado intersticial puro, infiltrado intersticial vinculado con reforzamiento peribronquial, infiltrado intersticial relacionado con infiltrado intersticial asociado a nódulo único, infiltrado intersticial unido a consolidación, cavitaciones, absceso pulmonar y derrame pleural, reforzamiento peribronquial puro, reforzamiento peribronquial relacionado con condensación alveolar, consolidación y derrame pleural, infiltrado micro y macronodular y condensación alveolar, cavitaciones y radiología normal.

Conclusiones: Las principales manifestaciones radiológicas de la aspergilosis pulmonar en niños al momento del diagnóstico, cuando se usan técnicas de biología molecular, son: infiltrado intersticial puro e infiltrado intersticial relacionado con otros signos radiológicos como reforzamiento peribronquial en 66.6% de los casos de la serie estudiada. Cuando el diagnóstico se realiza de manera temprana, ciertas manifestaciones radiológicas, como infiltrado micronodular, infiltrado macronodular, cavitación, abscesos y derrame pleural, son poco comunes.

Palabras clave: Aspergilosis, infiltrado intersticial, reforzamiento peribronquial, cavitación, absceso pulmonar.

Abstract

Background: Aspergillosis is an opportunist mycosis caused by *Aspergillus* species. It affects most often severely immunodeficiency virus infected children with marked neutropenia.

Objective: To describe the radiologic images of pulmonary aspergillosis in early diagnosed cases, based on the presence of galactomanan antigen with monoclonal antibodies for *Aspergillus* species.

Material and methods: The study included clinical and radiologic information of children, males and females, whose age ranged from one day to 18 years with clinical and radiologic diagnoses of aspergillosis confirmed by detection of galactomanan antigen with monoclonal antibodies for *Aspergillus* species in blood serum. The patients were hospitalized in different departments and services or both, at the Instituto Nacional de Pediatría, in Mexico. Chest X rays were studied prior to the diagnosis and following the confirmed diagnosis.

Results: The radiologic patterns prior to the diagnosis were: pure interstitial infiltrate in one case; interstitial infiltrate with marked peribronchial pattern, two cases; pure marked peribronchial pattern, five cases; parahilar infiltrate with consolidation in one case; interstitial infiltrate with alveolar consolidation in one case and normal radiologic findings in five cases.

The radiologic patterns found at the time of the diagnosis were: "pure" interstitial infiltrate, three cases; interstitial infiltrate and increased peribronchial markings, two cases; interstitial infiltrate with micro and macronodular infiltrate, one case; parahilar and basal condensation, two cases; interstitial infiltrate with consolidation, cavitation, pulmonary abscess and pleural effusion, one case; cavitations, one case; normal pattern, one case.

Conclusions: The main early radiologic findings of pulmonary aspergillosis in children at the time of diagnosis based on fast molecular biology techniques are the presence of interstitial infiltrate or interstitial infiltrate plus other radiologic findings such as enhanced peribronchial markings in ten cases of this study (66.6%). Other radiologic findings such as micro or macronodular infiltrate, cavitation, abscesses and pleural effusion are uncommon.

Key words: Aspergillosis, pulmonary radiologic involvement, increased peribronchial markings, cavitation, pulmonary abscess.

Introduction

Invasive aspergillosis is seen almost exclusively in severely immunodeficient children with marked neutropenia. The main clinical forms are pulmonary, sinus and disseminated.^{1,2}

The disease is mostly caused by three fungal species: *Aspergillus fumigatus*, *Aspergillus flavus* and *Aspergillus niger*; however, there are over 300 species capable of causing the disease.³

In most cases the infection is acquired through inhalation of air-borne spores present in ambient air, on the ground, in plants, in organic debris, spoiled vegetables, dust from construction work, air ducts, and other sources.^{1,2}

The most common predisposing factors are conditions leading to marked neutropenia, such as leukemia, the use of strong chemotherapy, malnutrition and the acquired immunodeficiency syndrome (AIDS); in this latter situation, the disease shows as a symptomatic invasive disease.^{4,5}

Invasive pulmonary aspergillosis is an unusual clinical condition with a poor prognosis seen in severely immunodepressed patients.¹⁻⁵ It presents as a uni or bilateral pneumonic condition which may lead to necrotising pneumonia or to lung empyema, with fever, mucopurulent expectoration, hemoptysis, malaise and weakness. Most cases have respiratory distress in a few hours. The infectious process may progressively involve the liver, intestine, spleen, heart and central nervous system.⁶⁻¹¹

Galactomanan antigen by means of monoclonal antibodies through agglutination of latex particles has a sensitivity ranging from 27 to 70% and a specificity ranging from 88 to 90%. This test has a high specificity, but a low sensitivity in cases of invasive pulmonary aspergillosis.^{1,2,12} Sensibility is dependent especially on the levels of circulating antigen. The test with latex particles is considered positive on detection of 15 ng/mL of serum antigen. On the other hand, 1 ng/mL of circulating antigen has been detected

with the sandwich-ELISA test. However, this greater sensitivity leads to a larger number of false positive results.^{13,16}

Radiologic images of invasive pulmonary aspergillosis during its early stages have been seldom studied. Radiologic findings in the invasive pulmonary infection are described as those seen in bronchopneumonia with infiltrations and multiple condensed areas or interstitial infiltrate and subsegmental or segmental consolidation.^{14,15}

An early diagnosis by means of a chest computerized axial tomogram (CAT scan) permits a reliable diagnosis of invasive pulmonary aspergillosis as it depicts segmental consolidation areas with or without nodules.

Patients with neutropenia and lower airways involvement exhibit peribronchial consolidation areas or centrolobular nodules.^{3,14} Nonetheless, CAT scan sensitivity and specificity in patients with neutropenia has not been carefully studied.¹⁵

The treatment of choice for invasive forms of aspergillosis is the use of amphotericin B at the dose of 1 to 1.5 mg/kg/day.³ In most publications, the length of treatment has been based on the clinical response of the patient, the lack of *Aspergillus* growth in culture media and the persistent negativity of *Aspergillus* specific antigen.¹⁶

The purpose of this study is to describe the radiologic patterns of early pulmonary aspergillosis by means of the detection of galactomanan antigen with monoclonal serum antibodies.

Material and methods

The clinical charts and X rays of hospitalized patients with aspergillosis studied at the Instituto Nacional de Pediatría from November 4, 1998 to November 30, 2000 were analyzed. The diagnosis was based on laboratory findings: direct exam of expectoration or bronchial aspirate cleared with potassium hydroxide; culture in Sabouraud medium; detection of serum galactomanan antigen by means of monoclonal antibodies and X ray studies.

An early diagnosis based on clinical findings was defined as that in which patients with confirmed aspergillosis had not reached the stage of respiratory distress either clinically or gasometrically inherent to invasive bronchopulmonary aspergillosis.

The following variables were recorded: sex, age, original disease, total neutrophil count, chemotherapy and/or steroid treatment; initial chest X ray findings and X ray findings during the disease.

There were 15 children of either sex, ages 1 day to 18 years.

* Department of Parasitology and Mycology.

** Department of Radiology, Instituto Nacional de Pediatría.

*** Pediatric Nephrologist.

**** Department of Health Attention, Universidad Autónoma Metropolitana, Xochimilco.

¹ Pediatric Immunologist and Allergologist.

² Department of Hematology, Instituto Nacional de Pediatría.

Corresponding author: Óscar Vázquez-Tsuji MD. Servicio Clínico de Parasitología y Micología. Instituto Nacional de Pediatría. Insurgentes Sur 3700-C, Col. Insurgentes Cuicuilco, Mexico City 04530. Recibido: marzo, 2002. Aceptado: abril, 2002.

Table 1. Radiologic patterns in children's pulmonary aspergillosis

<i>Case # Age Sex</i>	<i>Basic disease</i>	<i>Neutrophil Count</i>	<i>Chemotherapy and steroids</i>	<i>Prior X rays</i>	<i>X rays during the disease</i>	<i>Post-treatment X rays</i>
1 10 y F	Acute myelocytic leukemia (AML)	1100	Transretinoic acid, demorubicin, M2 cytonine arabinosidev	Middle enhanced peribronchial markings	Increased peribronchial markings; moderate interstitial parahilar and interstitial infiltrate	Normal
2 5 y F	Acute lymphocytic leukemia (ALL) L1	1500	Cycle of metotrexate	Enhanced peribronchial markings	Increased peribronchial markings	No follow-up
3 5 y F	ALL-L2	148	Cyclophosphamide Adryamicin	Normal	Bilateral parahilar interstitial infiltrate, predominantly right basal	Pulmonary overdistention with minimal enhanced markings
4 5 y F	ALL-L2	897	Cyclophosphamide Cytosine arabinoside	Minimally enhanced peribronchial and right basal markings	Increased peribronchial markings with bilateral interstitial infiltrate predominatly basal and parahilar	Increased right basal peribronchial markings
5 2 y F	ALL-L2	<100	Vincristine, adryamycin, prednisone, metotrexate	Normal	Bilateral interstitial infiltrate	No follow-up
6 3 y M	Paratesticular rhabdomyosarcoma	<100	Vincristine, cyclophosphamide, adryamycine, cisplatinum	Parahilar and left apical interstitial infiltrate	Right apical parahilar interstitial infiltrate. Left parahilar nodular lesion	Increased disseminated left parahilar infiltrate
7 9 y M	ALL-L2	<100	Vincristine, prednisone, L-asperginase, intrathecal metotrexate	Interstitial infiltrate; alveolar consolidation pattern; right aereal bronchogram	Left parahilar interstitial infiltrate; alveolar condensation; images aereal bronchogram; right condensation; parahilar and basal cavitation; increased interstitium; lung abscess pattern and pleural effusion	Deceased

<i>Case # Age Sex</i>	<i>Basic disease</i>	<i>Neutrophil Count</i>	<i>Chemotherapy and steroids</i>	<i>Prior X rays</i>	<i>X rays during the disease</i>	<i>Post-treatment X rays</i>
8 16 y M	AML-M2	<100	Adryamycine, prednisone, cytosine arabioside, vyncristine, intrathecal metotrexate	Normal	Normal	Interstitial infiltrate; alveolar consolidation; bilateral aereal bronchogram pattern
9 13 y F	Hepatocarcinoma	<100	Carboplatinum, etoposide	Normal	Left parahilar and left basal consolidation	Right basal pleural reaction
10 1 y M	AML-M2	594	Transretinoic acid	Interstitial infiltrate; bilateral peribronchial enhanced markings	Increased interstitial infiltrate with micronodular infiltrate	Increased peribronchial markings
11 M 4 y	Wilms tumor	<100	Vyncristine, actinomycin D, dexametasone	Increased peribronchial markings	Alveolar consolidation; righ apical and basal aereal bronchogram; increased peribronchial and left peribronchial markings; apical consolidation and pleural effusion	Deceased
12 14 y M	Mediastinal tumor	<100	Carboplatinum, etoposide	Right parahilar infiltrate and consolidation areas	Increased condensation; aereal bronchogram patterns; large right parahilar consolidation	No follow-up
13 11 y F	ALL-L1	1600	Metotrexate, 6 mercaptopurin	Increased right basal peribronchial markings; minimal interstitial infiltrate	Generalized increased interstitial infiltrate; minimal aereal bronchogram pattern	Interstitial pattern; micronodules
14 7 y F	AAL-L1	<100	Metotrexate	Moderately increased peribronchial markings	Micro and macronodular infiltrate; alveolar condensation; aereal bronchogram; lymph nodes in the right helium; bilateral pneumothorax	Deceased
15 13 y	Chronic granulocytic leukemia (CGL)	<100	Busulfan	Normal	Interstitial pattern; micro and macronodular pattern	Normal

Results

The diagnosis of aspergillosis was confirmed by laboratory studies; there were eight boys and seven girls; 11 patients had leukemia; four had other types of malignancy. Every patient had received chemotherapy or steroids or were under treatment with these drugs when the diagnosis was made. Eleven patients had marked neutropenia with total counts of less than 100 neutrophils. Three (20%) patients died (table 1).

Cough was a constant symptom in every patient; it was present on an average of 17 days prior to diagnosis, ranging from three to 32 days.

Chest X rays on admission before pulmonary aspergillosis was suspected showed bilateral interstitial infiltrate and other abnormalities in these patients (20%); one patient (6.6%) only had interstitial infiltrate. Five patients (33.3%) had normal chest X rays. Enhanced peribronchial markings were seen in five patients (33.3%). One patient (6.6%) exhibited alveolar condensation prior to the presence of symptoms. One case (6.6%) had parahilar infiltrate with consolidation. During the early stages of pulmonary aspergillosis no cases of micro or macronodular infiltrate, of cavitation, pleural effusion or nodules were detected (table 2).

Table 2. Radiologic patterns in children prior to the diagnosis of pulmonary aspergillosis (n = 15)

Radiologic pattern	Number of patients	Percentage
Interstitial infiltrate	1	6.6
Interstitial infiltrate plus increased peribronchial markings	2	13.3
Interstitial infiltrate plus alveolar condensation	1	6.6
Increased peribronchial markings	5	33.3
Parahilar infiltrate; consolidation	1	6.6
Normal	5	33.3

Chest X rays taken at the time of a confirmed diagnosis of invasive pulmonary aspergillosis showed interstitial infiltrate in three cases (20%); interstitial infiltrate plus enhanced peribronchial markings in two cases (13.3%); interstitial infiltrate plus micro and macronodular infiltrate in one case (6.6%); interstitial infiltrate plus a single nodular lesion in one case (6.6%). Isolated enhanced peribronchial pattern was present in one case (6.6%).

In five patients (33.3%) there were radiologic changes indicating the progression of the disease, i.e. micro and

macronodular images, cavitations, pleural effusion and consolidation.

Only one case had normal radiologic findings; this patient had a total count of 1,400 leukocytes (figures 1 to 5). Another patient had the largest number of pulmonary radiologic changes: interstitial infiltrate, alveolar condensation, right basal pulmonary condensation, basal cavitations, pulmonary abscess and unilateral pleural effusion (table 3).

The average time elapsed between the initial and the late chest X rays (when the patients had neutropenia and fever) was 13.6 days (range, five days-28 days).

Discussion

Radiologic changes in the early stages of pulmonary aspergillosis have not been extensively studied; there are scant reports on isolated cases in children.^{29,33} Those found in this study must be differentiated from other conditions which may appear with radiologic patterns of bilateral interstitial infiltrate, such as pneumocytosis, pulmonary infection by *Mycoplasma*, *Chlamidia* and other bacterial or viral infections. Most reports concerning the differential diagnosis in several entities causing interstitial pulmonary infiltrate fail to include aspergillosis in the differential diagnosis.

The early diagnosis of pulmonary aspergillosis by means of molecular biology techniques such as the detection of galactomanan antigen with monoclonal antibodies is associated with early radiologic changes which are not mentioned in most reports, since the majority of these cases are almost invariably diagnosed during the late stages of the disease.

Early radiologic changes in pulmonary aspergillosis depend on how soon the diagnosis is made and on the immunologic condition of the patient. According to our study, the radiologic findings in the early stages of pulmonary aspergillosis in children, prior to the diagnosis are an interstitial infiltrate by itself or associated to enhanced peribronchial markings in 60% of the patients or less frequently with other radiologic findings.

In the early stages of pulmonary aspergillosis chest X rays may be normal, especially in patients with marked leukopenia, when no pulmonary infiltrates are present.

Radiologic findings such as micro or macronodular infiltrates, cavitations, abscesses and pleural effusion were infrequent probably owing to the fact that the diagnosis of pulmonary aspergillosis was made in the early stages of the disease, before the development of respiratory distress or of other complications.

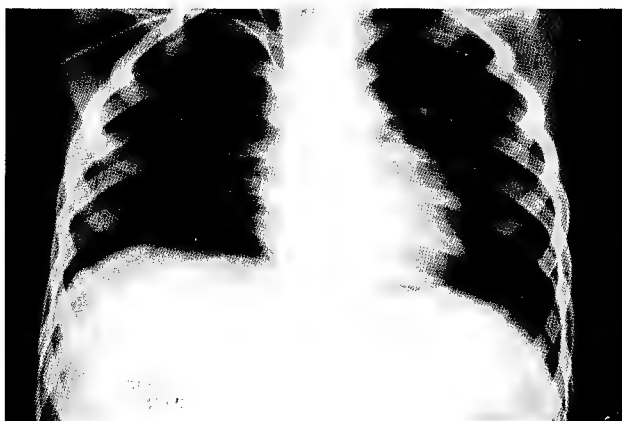

Figure 1. Chest X rays of a patient with aspergillosis. There is a parahilar interstitial infiltrate in the right apical area and a left parahilar nodular lesion.

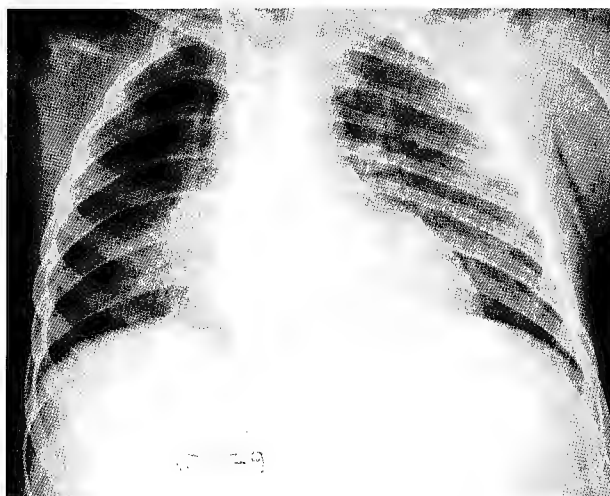


Figure 3. Alveolar consolidation with an apical parahilar and a basal bronchogram with increased left peribronchial markings and a left apical consolidation; a mild right pleural effusion is present.

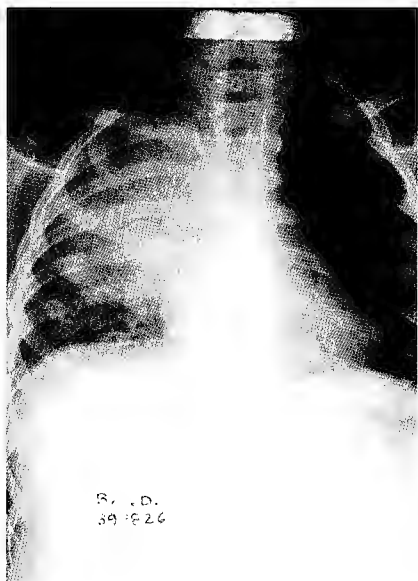


Figure 2. This chest X ray shows a left parahilar interstitial infiltrate; there is a pattern of alveolar condensation and a bronchogram.

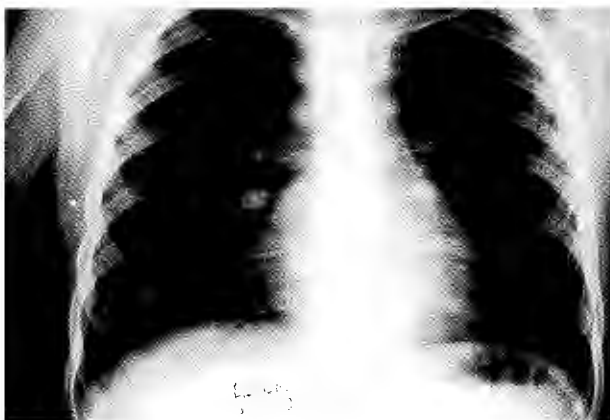

Figure 4. A chest X ray showing a generalized interstitial infiltrate and a bronchogram.

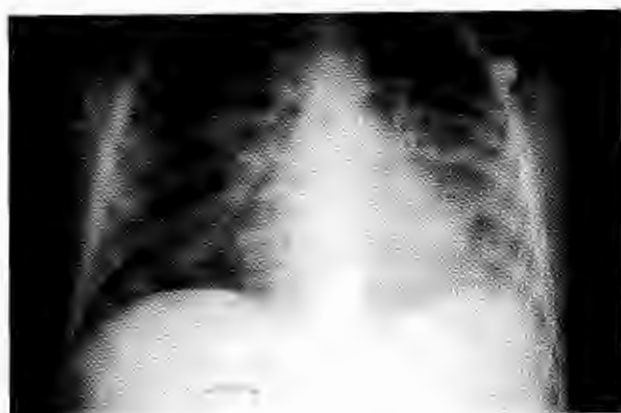The diagnosis of pulmonary aspergillosis is very difficult because of its polymorphic clinical features and because most hospital laboratories are not equipped with the necessary tools for the early diagnosis of the infection. Most facilities can only do direct examinations and culture of sputum or of bronchial aspirate. In addition, the presence of one or more positive cultures for the same species of *Aspergillus* does not necessarily indicate that an infection exists; furthermore cultures may be positive in cases of saprophytic colonization of upper airways and in patients with allergic broncho-

pulmonary aspergillosis. In this latter case there may be fever, cough and other respiratory manifestations such as rales and respiratory distress in the absence of tissue invasion. Likewise, direct examination of sputum in search of septated dichotomized mycelia may be positive in cases with colonization of the upper airways.

The antigen detection test for *Aspergillus* by means of monoclonal antibodies has a low sensitivity which makes it necessary to do repeated tests as it only becomes positive in the presence of high blood concentrations of *Aspergillus*

Table 3. Radiologic patterns in children with pulmonary aspergillosis at the time of diagnosis (n = 15)

Radiologic pattern	Number of patients	Percentage
Interstitial infiltrate	3	20.0
Interstitial infiltrate plus enhanced peribronchial markings	2	13.3
Micro and macronodular infiltrate	1	6.6
Interstitial infiltrate; single nodular lesion	1	6.6
Parahilar interstitial infiltrate; consolidation; cavitations; lung abscess; pleural effusion	1	6.6
Increased peribronchial markings	1	6.6
Increased peribronchial markings; alveolar condensation; consolidation; pleural effusion	1	6.6
Micro and macronodular infiltrate; alveolar condensation	1	6.6
Parahilar and basal consolidation pattern	2	13.3
Cavitations	1	6.6
Normal	1	6.6

**Figure 5.** This chest X ray shows marked micro and macronodular infiltrate; alveolar condensation and a bronchogram.

antigens (15 ng/mL). However, a positive test is considered diagnostic when a patient has respiratory symptoms, and a positive sputum culture for septated dichotomized mycelium. It must be pointed out that other techniques are capable of detecting serum antigen levels as low as 1 ng/mL but this increase in sensitivity results in a larger number of false positive tests.^{16,17}

The introduction of more sensitive laboratory tests for an earlier diagnosis of invasive bronchopulmonary aspergillosis make it desirable to reassess criteria that have so far been used for the diagnosis of this disease.

REFERENCES

- Bonifaz A. *Micología Médica Básica*. México: Méndez Editores, 2000;pp361-76.
- Rippon J. *Tratado de Micología Médica*. México: Interamericana, 1990; pp668-703.
- Nelson. *Tratado de Pediatría*. México: McGraw-Hill, 1997; pp:1187-90.
- Janssen W. Outcome of ICU treatment in invasive aspergillosis. *Intensive Care Med* 1996;22:1315-22.
- Shetty D. Invasive aspergillosis in human immunodeficiency virus infected children. *Pediatr Infect Dis J* 1997;16:216-21.
- Glimp RA. Allergic bronchopulmonary aspergillosis. *Chest* 1981;80:85-94.
- Rosemberg M, Patterson R. Clinical and immunology criteria for the diagnosis of allergic bronchopulmonary aspergillosis. *Ann Intern Med* 1977;16:405-14.
- Cahill B. Aspergillus airway colonization and invasive disease after lung transplantation. *Chest* 1997;112:60-1164.
- Bautati E, Anaissie E. Fusarium a significant emerging pathogen in patients with hematologic malignancy: ten year's experience at a cancer center and implications for management. *Blood* 1997;90:999-1008.
- Wald A. Epidemiology of Aspergillus infections in a large cohort of patients undergoing bone marrow transplantation. *J Infect Dis* 1996;175:1459-66.
- Herbert A. Fungal pneumonia invasive pulmonary Aspergillosis. *Chest* 1981;80:220-1.
- Masahiro K, Yoshinobu K. Frequent false-positive results of Aspergillus latex agglutination test. *Cancer* 1999;86:274-81.
- Hopwood V, Johnson ME, Foot ABM, Evans EGU, Warnock DW. Use of the Pastorex Aspergillus antigen latex agglutination test for the diagnosis of invasive aspergillosis. *J Clin Pathol* 1995;48:210-3.
- Wright M, Fikring S. Aspergillosis in children with acquired immune deficiency. *Pediatr Radiol* 1993;23:492-4.
- Hyung J. Invasive pulmonary Aspergillosis. Prediction at thin-section CT in patients with neutropenia. *Radiology* 1998;208:777-82.
- Vázquez TO, Gutiérrez CP, Campos RT, Rojas GA, Martínez BI, García CG. Utilidad de la detección de antígeno de Aspergillus en el rastreo y diagnóstico de aspergillosis nosocomial. *Rev Mex Patol Clin* 2001;48:70-7.
- Vázquez TO, Campos RT, García CG, Martínez BI. Abordaje diagnóstico y terapéutico de la aspergillosis en el paciente neutropénico. *Acta Pediatr Mex* 2001;22:329-31.
- Patterson JF, Zidouh A, Minitier P, Andriole VT, Patterson TF. Hospital epidemiologic surveillance for invasive aspergillosis: patient demographics and the utility of antigen detection. *Infect Control Hosp Epidemiol* 1997;18:104-8.